

Abdominal Aortic Aneurysm Presenting to the Orthopaedic Clinic as Posterior Hip and Low Back Pain

Aaron Marcel MS, John Jovan BS, Karen Myrick DNP
Frank H. Netter MD School of Medicine at Quinnipiac University

Background

- Abdominal aortic aneurysm (AAA) is a permanent dilatation of the infrarenal aorta that is 3 cm or greater in diameter or equivalent to 1.5 times the normal anteroposterior diameter
- Risk factors for AAA include:
 - Smoking
 - Male sex
 - Age greater than 65 years old
 - High systolic blood pressure (SBP)
 - High body mass index (BMI)
 - High serum triglycerides
 - High low-density lipoprotein (LDL)
 - Family history of AAA
 - Coronary artery disease (CAD)
 - Atherosclerosis
 - Stroke
 - Diabetes mellitus with concomitant CAD and peripheral artery disease (PAD)
- Most unruptured AAA are asymptomatic and are found incidentally while investigating some other pathology
- When symptomatic, unruptured AAA may present with unexplained abdominal discomfort and pain that radiates to the back, flank, or groin, as well as a pulsatile abdominal mass with or without a bruit heard at the mass

Case Presentation

History of Present Illness

- November 27, 2022, a 70-year-old male with a history of bilateral total hip arthroplasty (THA) presented to the orthopaedic urgent care clinic with a chief concern of posterior right hip and low back pain persistent over the previous 3 days
- The patient noticed the pain after going for a long walk on Thanksgiving Day
- Denied any recent trauma, injury, or falls
- Denied abdominal pain and constitutional symptoms such as headache, fever, chills, nausea, lightheadedness, or dizziness. The review of systems was unremarkable.

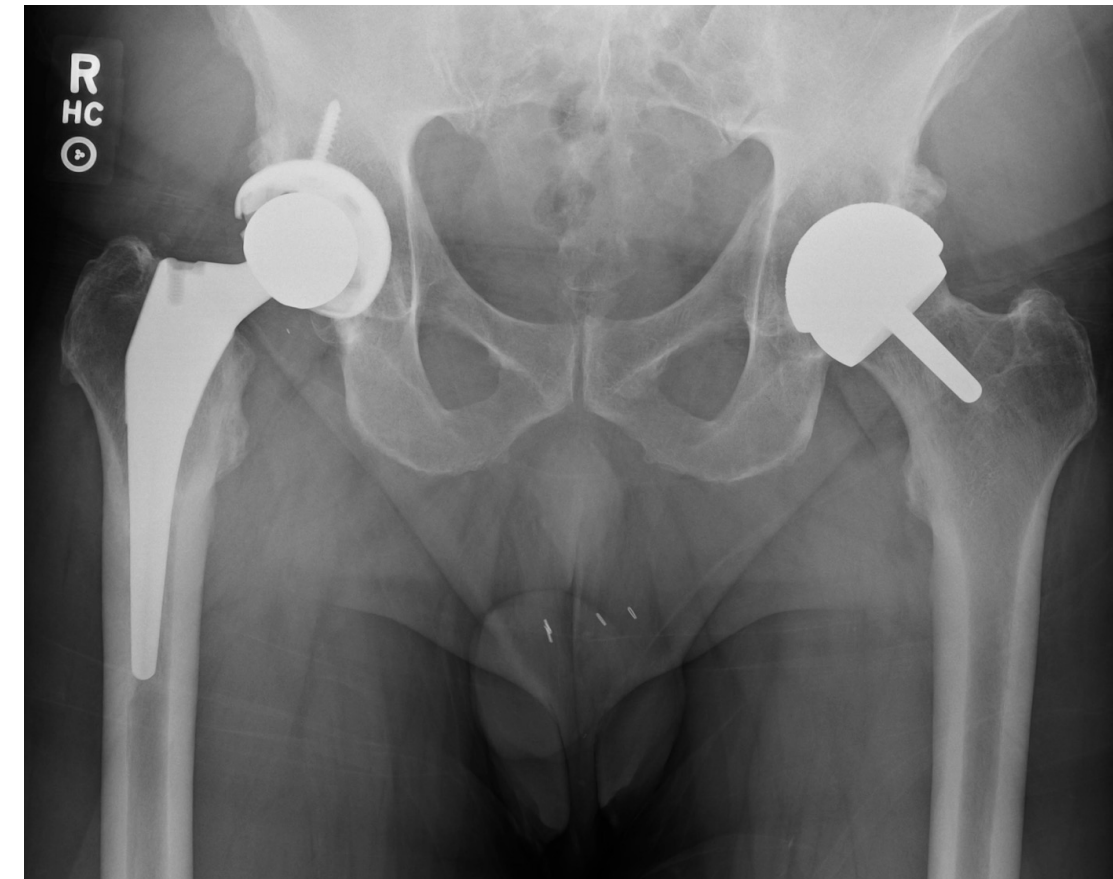
Past Medical History

- Hypertension, hyperlipidemia, coronary artery disease, type 2 diabetes mellitus, and peripheral artery disease
- Appendectomy (1972), vasectomy (1981), coronary artery bypass graft (CABG) (2009), and bilateral total hip arthroplasty (right 2014, left 2019)

Examination

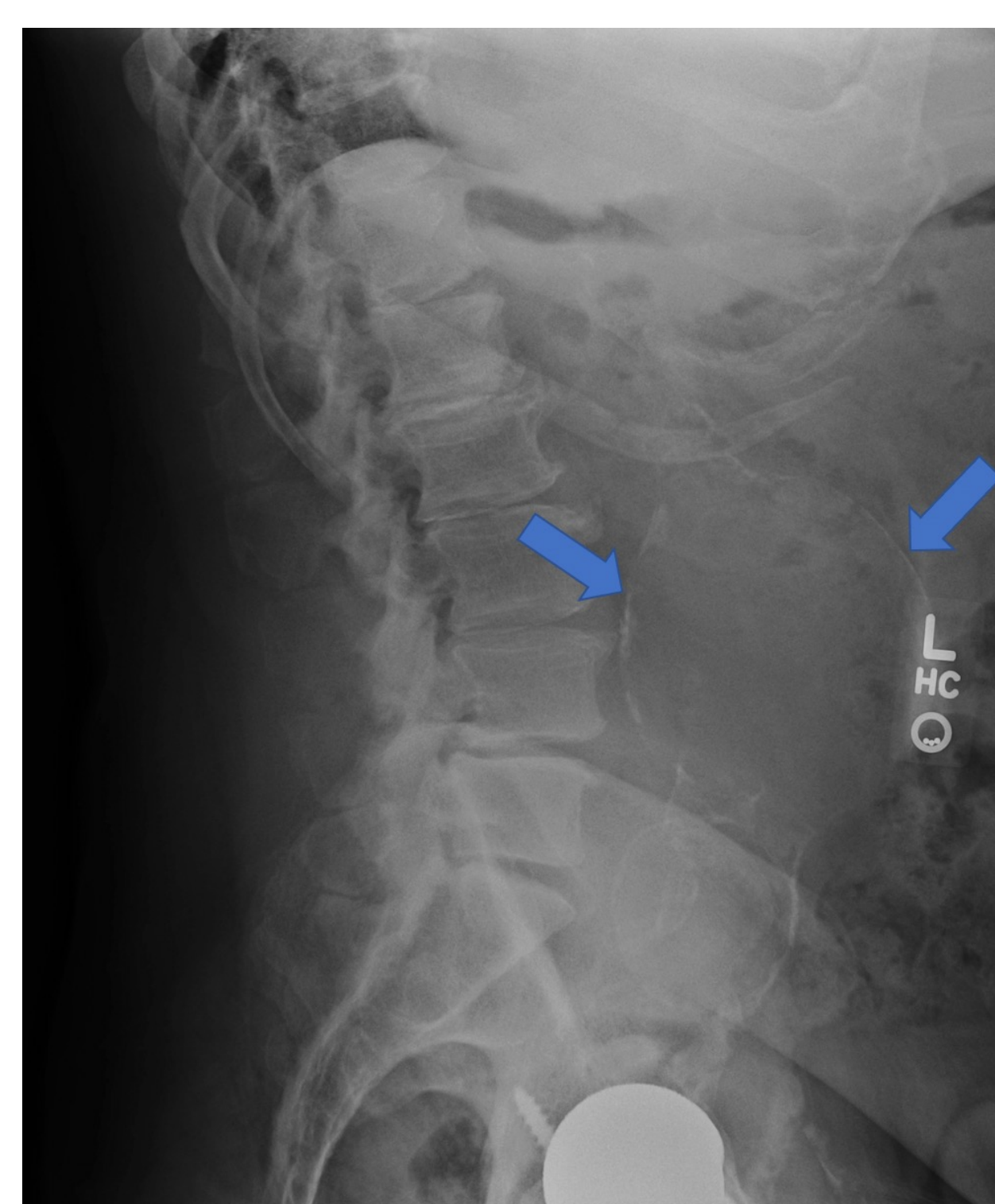
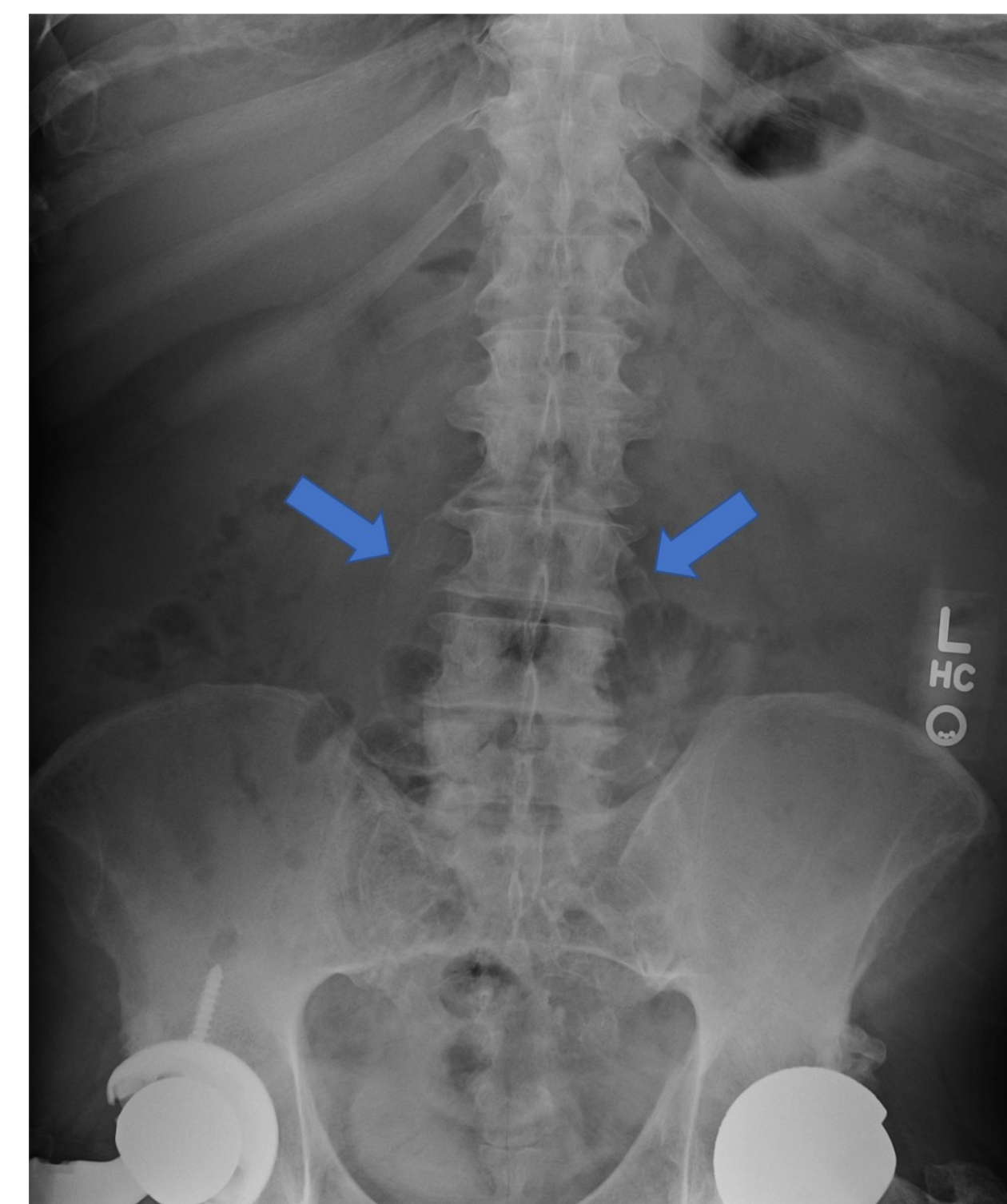
- Awake, alert, and oriented
- Antalgic gait with a painful right leg
- Inspection of the right hip and low back revealed focal, reproducible tenderness along the posterior aspect of the right lumbosacral joint
- No sciatic notch tenderness
- No significant tenderness to palpation over the midline of the lumbar spine and no significant tenderness over the right flank
- Range of motion of the hip was full without any significant discomfort
- Neurovascular assessment of both lower extremities was intact

Imaging



AP radiograph of bilateral total hip arthroplasty. No prostheses wear or peri-prosthetic fracture is noted. Additionally, there are no bony abnormalities or dislocations.

AP radiograph of the lumbar spine demonstrating a calcified outline of an unruptured abdominal aortic aneurysm (blue arrows).



Lateral radiograph of the lumbar spine demonstrating a calcified outline of an unruptured abdominal aortic aneurysm (blue arrows).

Discussion

- Our case report demonstrates an incidental finding of a large, unruptured AAA during a workup for a chief concern of posterior right hip and low back pain
- In the orthopaedic clinic, an abdominal aortic aneurysm is not high on the differential for a patient presenting with posterior hip and low back pain
- With a chief concern of posterior hip and low back pain in a patient with a history of bilateral THA, the initial assumption would be muscle strain or a complication related to the patient's prostheses
- Factors that point toward orthopaedic etiology:
 - Patient ambulated with a painful right leg and their gait was antalgic
 - Reproducible tenderness on the posterior aspect of the right lumbosacral junction
- Factors that point away from orthopaedic etiology:
 - Patient denied any trauma, injury, or falls (non-traumatic causes such as infection and osteolysis must still be considered)
 - Range of motion was fully intact with no discomfort
- Patient's risk factors for AAA:
 - Hypertension
 - Hyperlipidemia
 - Coronary artery disease
 - Type 2 diabetes mellitus
 - Peripheral artery disease
 - Male sex
 - Age > 65 years
- The patient's significant cardiac and vascular history, in conjunction with the HPI and negative findings on orthopaedic physical exam, should logically lead a provider towards a non-orthopaedic etiology and raise suspicion for an AAA

Existing Literature

- Smith (1987) - 66-year-old male patient with an 8-month history of progressive left hip pain who was incidentally found to have an unruptured AAA
- Baskaran (2013) - 58-year-old patient with a 6-month history of progressively worsening left hip pain associated with unintentional weight loss of 38 kg and tender bilateral testicular swelling
- Low back pain has been a well-documented presentation of an unruptured AAA in several case reports

Conclusion and Teaching Point

In conclusion, an unruptured AAA may be an atypical cause of posterior hip and low back pain. Orthopaedic providers should include an unruptured AAA on the differential for a patient presenting with these concerns, particularly in the context of significant cardiac and vascular history, significant risk factors, and negative orthopaedic findings on physical exam. Additionally, orthopaedic providers should focus on a holistic approach to patient care, considering all aspects of the history of present illness, past medical history, family history, social history, and physical exam when exploring differential diagnoses.

Contact

Aaron Marcel MS
Frank H. Netter MD School of Medicine
Aaron.Marcel@Quinnipiac.edu

References

- Aggarwal S, Qamar A, Sharma V, Sharma A. Abdominal aortic aneurysm: A comprehensive review. 2011;16(1):11–15. doi:ecc16011 [pii]
- Baskaran D, Ashraf N, Ahmad A, Menon J. Inflammatory abdominal aortic aneurysm: a persistent painful hip. 2013 Sep 13;2013:10.1136/bcr-2013-009150. doi:10.1136/bcr-2013-009150
- Chaikof EL, Dalman RL, Eskandari MK, Jackson BM, Lee WA, Mansour MA, et al. The Society for Vascular Surgery practice guidelines on the care of patients with an abdominal aortic aneurysm. 2018 Jan;67(1):2-77.e2. doi:S0741-5214(17)32369-8 [pii]
- Smith DL, Campbell SM. Unruptured abdominal aortic aneurysm mimicking hip joint disease. 1987 Feb;14(1):172–173.